

Gruber-Frantz tumor

A. P. Koshel^{1,2}, S. S. Klovov^{1,2}, K. M. Popov¹, S. V. Vtorushin^{2,3}, M. V. Zav'yalova^{2,3}, I. V. Stepanov^{2,3}, T. V. Dibina¹, Y. B. Mironova^{1,4}, Y. S. Drozdov³, V. A. Avkhimenko⁵

¹Medical center n. a. G. K. Zherlov, Seversk, Russian Federation

²Siberian State Medical University, Tomsk, Russian Federation

³Tomsk Research Institute of Oncology, Tomsk, Russian Federation

⁴Tomsk Regional Oncological Clinic, Tomsk, Russian Federation

⁵Siberian Federal Research & Clinical Centre of the Federal Medical & Biological Agency, Seversk, Russian Federation

Key words: pancreas, pancreatic tumor, Frantz tumor, immunohistochemistry, treatment

Solid pseudopapillary tumor (SPPT) is a rare tumor of the pancreas with unknown histogenesis. In most reports it is regarded as a frontier malignancy with a good prognosis (5-year survival rate is greater than 97%) [2, 7, 10, 12, 15, 18].

According to statistics, the frequency of detection of this tumor is 1% of all tumors of the exocrine pancreas, and in recent years the incidence of this disease tends to increase. With the accumulation of clinical data, it has been suggested that SPPT can be more than 24% of all surgically resected pancreatic cystic neoplasms and approximately 30% of all tumors of the pancreas in patients up to 40 years [1, 8].

For the first time the tumor was diagnosed in 1927 at the 19-year-old girl, but as a special form described only in 1959 by V. K. Frantz [5].

Etiology and risk factors of SPPT, unfortunately, are not known. These tumors were detected in pregnant women and patients who have had an injury, but conclusive evidence that would consider these factors cause SPPT, has been received. According G. A. Stashuk et al. (2006), the pregnancy, as well as trauma, provoking the symptoms already had previous formation.

T. Papavramidis et al. (2005) conducted the analysis of 718 cases of the diagnosis SPPT given in English literature indicate that the disease is most commonly diagnosed in young women, whose average age is 22. In fairness it must be noted that there are descriptions of these tumors in children and men [7, 13, 17, 18].

The clinical picture of SPPT is generally not specific. Patients may complain of indigestion, unmotivated weight loss, nausea, vomiting, as well as the presence of the bulk of formation in the abdomen. Almost half of the cases the tumor is found in the survey about other pathology [1].

Very rarely (for localization in the head of the pancreas) can cause swelling of obturation of the bile duct to the development of jaundice. There are cases of spontaneous rupture of the tumor with the development of hemoperitoneum. It is extremely rare tumor manifests as acute pancreatitis or post-traumatic cysts of the pancreas [6, 16].

X-ray, ultrasonography and computed tomography play a leading role in the diagnosis of SPPT.

In computed tomography tumor looks clearly defined rounded hypodense formation, represented by solid and cystic components in different ratios without the internal partitions. The tumor separated from the surrounding tissue of the pancreas, and has a fibrous capsule, in which calcifications may be found [14]. The solid portion is located mainly on the periphery, with intravenous contrast enhancement stores [9].

In ultrasonography neoplasm is presented as iso- or hypoechoic formation on the background of unchanged pancreatic parenchyma.

Needle biopsy may help in establishing the diagnosis before surgery, however, according to most researchers, it is not necessary [1, 4].

The differential diagnosis is carried out with cystic or solid masses of the pancreas, especially with pseudocysts, mucinous tumors, cystadenoma, carcinoma, pancreatoblastoma, hemangioma, lymphangioma, and finally with angiosarcoma.

Inflammatory pseudocyst usually appears after abdominal injury or an episode of acute pancreatitis. Endocrine tumors are characterized by older age. Pancreatoblastoma is common in men. Acinar tissue tumors are always malignant and almost equally common in men and women aged 60-70 [1, 5].

Radical resection, if technically feasible, is the method of choice in the treatment of SPPT. Any techniques can be used: Whipple's surgery, pyloropreserving pancreatoduodenal resection, distal pancreatectomy, enucleation or resection of the tumor. Single metastases from the liver are to be removed. Puncture treatment is not indicated. Chemotherapy has no proven efficacy.

The prognosis after removal of the tumor is generally favorable, even with metastasis or recurrence of the tumor [11]. Ways of tumor metastasis: lymph nodes, liver, spleen, mesocolon [1].

Histologically, in most cases reveal solid monomorphic growth on the periphery of the tumor, as in the center of the tumor cells become discohesive and form pseudopapillae surrounded by cavities. Degenerative changes can progress not only to form pseudopapillae; in some cases there is extensive fibrosis within the tumor foci of calcification and ossification, lots of foamy macrophages, hemorrhages, deposits of cholesterol crystals.

To date, the diagnosis of SPPT leading role belongs to immunohistochemical study, which determines the expression of epithelial (MNF116; CAM5,2; VegER4, EMA, etc.), endocrine (siaptophizin) and melanin-cellular (HMB45) markers.

Various synonyms: papillary cystic neoplasm, papillary epithelial neoplasm, papillary and cystic tumor, papillary and cystic epithelial carcinoma, papillary and solid neoplasm, solid and cystic tumor of acinar cells and finally the Gruber-Frantz tumor (Frantz-Gruber), make it difficult to estimate the frequency of the occurrence of tumors, so the real level data SPPT is difficult to assess. In 1996, the World Health Organization (WHO) has renamed it as "solid pseudopapillary tumor" for the international histological classification of tumors of the exocrine part of the pancreas.

We present the observation of a young woman, in whom SPPT of the pancreas was found by accident.

Patient M., born in 1981, was delivered to Medical center n. a. G. K. Zherlov on 24.11.2014 in a planned manner. On admission she complained of palpable formation in the left upper quadrant. No other complaints about the digestive system. Satisfactory nutrition. Body weight is stable. No dysuria.

From medical history we know that in May-June 2014 on a background of overall health, she saw the formation of the left upper quadrant in the movement, in the supine position. Over time formation has increased in size. At the beginning of November 2014 formation began to be palpated by hands, there was a visual "bulging" belly.

Abdominal MRI with gadolinium bolus of contrast agent from 29.10.2014: the liver is enlarged, signs of pathological accumulation of paramagnetic material are not revealed. In the tail there is a cystic formation of the protein content with a thin capsule, the inhomogeneous structure with the features of the wall surround soft-tissue component accumulating the paramagnetic into the venous phase (Fig. 1).

The body of the pancreas is stretched over the surface of the cyst, the wall of the stomach is pushed aside, and has sharp edges on the border of the tumor. Wirsung's duct is not dilated. Regional lymph nodes were not enlarged.

Conclusion: MR signs of serous cystadenoma of the pancreas tail, morphological verification is suitable.

Transabdominal ultrasound examination of the pancreas from 25.11.2014: the contours are rough and fuzzy at the tail. Dimensions: head 22 mm, body 15 mm, increased echogenicity, heterogeneous structure. The projection of the tail hypoechogenic formation of rounded shape, 100×89×96 mm, with a relatively thick to 5-8 mm wall and hyperechoic heterogeneous content — parietal hyperechoic massive overlay (Fig. 2, 3a, 3b), a large amount of easily moved echo meal.

Three-dimensional ultrasonography (Fig. 4) after the post-processing in a transparent mode with smoothing the surface — the inner contour of formation is lumpy,

fragments with a sharply linear hyperechoic inclusions — fibrosis, wall is significantly thickened (Fig. 4b).

In the DRC the blood flow at the periphery of formation, several vessels of the tail of the pancreas pushed anteriorly, formation has its own vascular pedicle (Fig. 5), in the apparatus function multislice during rotation of three-dimensional array of well-rendered connection with pancreatic parenchyma (Fig. 6).

Conclusion: formation with a non-uniform structure in the projection of the tail of the pancreas.

FGDS: pathology of relief of the esophagus and stomach mucosa, no duodenum.

On the basis of preoperative data we diagnosed: Cyst of the tail of the pancreas? Retroperitoneal cyst on the left?

On 26.11.2014 the operation was performed: resection of the tail of the pancreas. High-median laparotomy. The liver is not changed. Omental bursa has cystic formation of 10×10 cm in size, which comes from the tail of the pancreas. Pancreatic tissue of normal color and consistency, is not increased. The spleen is not interested. The peritoneum is dissected, the cyst with a tail is delivered to the wound (Fig. 7). Upon allocating cyst, it is found that artery to 3 mm in diameter comes to it and vein diameter of 6-7 mm comes out. Tissue of the pancreatic tail is spread in the cyst, sometimes in the form of islets. Resection of the tail with formation is performed. Control of hemostasis, and foreign bodies, layering wound closure of the anterior abdominal wall. Nasogastric tube is established.

Preparation: cyst 10×10 cm, with a fragment of the pancreas. On a section with a dense cyst wall, the inner surface is lined with light brown glandular tissue, hemorrhagic luminal contents without clots (Fig. 8).

The morphological study of tumor. In the preparations of the macroscopically determined cystic formation tumor tissue is revealed, presented by monomorphic cells, of polygonal and irregular shape, with eosinophilic cytoplasm. The cell nuclei are normochromic, oval or angular. Mitosis in cells is not detected. Histarchitectonics is

heterogeneous, sometimes tumor cells are placed radially around the fibrovascular strands forming pseudopapillary and micropapillary structure (Fig. 9a), as well as structures such as rosettes and solid fields (Fig. 9b). Tumor stroma is presented by hyalinized thin fibrous layers. As part of the visual field is determined by the accumulation of extracellular pink masses. The capsule of the tumor is presented by hyalinized fibrous tissue. In some areas in the interior of the capsule walled foci of tumor tissue are detected. There is no spread of the tumor outside the capsule. No necrosis of the tumor tissue. From the capsule to the tumor pancreatic tissue is adjacent. Lobed gland structure is preserved, the typical structure of the islets of Langerhans.

To clarify its histotype, tumor is studied immunohistochemically.

In tumor cells lacking expression of cytokeratin AE1/AE3 (CloneAE1/AE3, Dako), cytokeratin 7 (CloneOV-TL 12/30, Dako), chromogranin A (Polyclonal, Dako), synaptophysin (CloneSY38, Dako), CEA (Clone II-7, Dako). Most tumor cells have a positive cytoplasmic staining for vimentin (Clone V9, Dako), α -1 antitrypsin (Polyclonal, Dako), marked focal nuclear-cytoplasmic staining for β -catenin (Clone E247, abcam). In tumor cells indicated a positive membrane staining for CD56 (Clone 123C3, Dako), a positive perinuclear staining of a dot-like to CD99 (Clone 12E7, Dako) and CD10 (Clone 56C6, Dako), nuclear staining for Cyclin D1 (Clone EP12, Dako) and progesterone receptor (ReceptorClonePgR636, Dako). Index proliferative activity, assessed by nuclear staining in the tumor cells Ki-67 (Clone MIB-1, Dako) was less than 0.5%. The results of the study are presented in Fig. 10.

Conclusion: The solid papillary tumor of the pancreas (Frantz-Gruber tumor) with the border-line (undefined) malignant potential (given the lack of evidence of vascular and extracapsular invasion, necrosis, nuclear polymorphism, low proliferative activity of cells).

12.04.2014 of (the 8th day) the patient was discharged under medical supervision in the place of residence.

The patient examined in 6 months in June 2015. No complaints, work at the same place, no data for relapse and progression of the process.

Finally, it should again be noted that the solid pseudopapillary tumor is a rare neoplasm of low malignant potential, which most often affects young women. Verification of pancreatic tumors, particularly neuroendocrine tumors, and with the complex and uncertain histogenesis, is impossible without complex morphological studies using modern diagnostic methods — immunohistochemistry and electron microscopy. Correct diagnosis is crucial to select the optimal treatment strategy in patients with tumors of the pancreas and determination of prognosis. Resection of tumor is the treatment of choice, and gives good long-term results.

References

1. Гордиенко Е.Н. Морфологическая и молекулярно-биологическая характеристика солидно-псевдопапиллярной опухоли поджелудочной железы/ Е.Н.Гордиенко. — Дисс. ... канд. мед.наук. М., 2014. — 140 с.
2. Сташук Г.А.Солидно-псевдопапиллярные опухоли поджелудочной железы (два клинических наблюдения) / Г.А.Сташук, Л.Е.Гуревич, М.В.Мокин // Вестн. рентгенол. и радиол.— 2006. — № 3. — С. 52–58.
3. Byron E.C. Solid and papillary epithelial neoplasm of the pancreas, diagnosis by cytology / E.C.Byron // South Med. J. — 1998. — Vol.91. — P. 973–977.
4. Endoscopic ultrasound-guided fine-needle aspiration cytology diagnosis of solid-pseudopapillary tumor of the pancreas. A rare neoplasm of elusive origin but characteristic cytomorphologic features /R.H.Bardales, B.Centeno, J.S.Mallery [et al.] //Am. J.Clin.Pathol. — 2004. — Vol. 121. — P. 654–662.
5. Frantz V.K. Tumors of the pancreas/ V.K.Frantz //In: Atlas of tumor pathology. — Washington DC: Armed Forces Institute of Pathology, 1959. — P. 32–33.
6. Frantz's tumour of the pancreas presenting as a post-traumatic pseudocyst / B.Hansson, G.Hubens, M.Hagendorens [et al.] //ActaChir. Belg. —1999. —Vol.99. — P. 82–84.
7. Meshikhes A.-W. N.Pancreatic pseudopapillary tumor in a male child /A.-W. N.Meshikhes, R.Atassi// J. Pancreas. — 2004. — Vol.5. — P. 505–511.
8. Papavramidis T.Solid pseudopapillary tumors of the pancreas: review of 718 patients reported in English literature/ T.Papavramidis, S.Papavramidis // J. Amer. Coll. Surg. — 2005. — Vol. 200. — P. 965–972.
9. Positive immunohistochemical staining of KIT in solid-pseudopapillary neoplasms of the pancreas is not associated with KIT/PDGFRA mutations/ D.Cao, C.Antonescu, G. Wong [et al.] // Modern Pathol. — 2006. — Vol. 19. — P. 1157–1163.

10. Solid-pseudopapillary tumor of the pancreas: a surgical enigma? / R.C.Martin, D.S.Klimstra, M.F.Brennan, K.C.Conlon // *Ann. Surg.Oncol.*— 2002. — Vol.9. — P. 35–40.
11. Solid and cystic papillary neoplasm of the pancreas: arare tumour in young women/ T.Darius, J.Brouwers, H.Van Dijck, P.Bernard // *ActaChir. Belg.* — 2006. — Vol. 106. — P. 726–729.
12. Solid and cystic papillary neoplasms of the pancreas : report of four cases /M. Zeytunlu,O. Firat, D. Nart [et al.] // *Turk. J. Gastroenterol.* — 2004. — Vol. 15. — P. 178–782.
13. Solid cystic tumor of the pancreas in elderly men: report of a case /H. Takahashi,K. Hashimoto, H. Hayakawa [et al.] // *Japan J. Surg.* — 1999. — Vol. 29. —P. 1264–1267.
14. Solid pseudopapillary carcinoma of the pancreas: differentiation from benign solid pseudopapillarytumour using CT and MRI / J.H.Lee, J.S.Yu, H.Kim [et. al.] // *Clin.Radiol.* — 2008. — Vol. 63, No 9. — P. 1006–1014.
15. Solid pseudopapillary neoplasm of the pancreas: report of a case after a 10-year follow-up and review of the literature / I.Petrakis, N.Vrachassotakis, N.Kogerakis [et al.] // *Pancreatology.* — 2001. — Vol.1. — P. 123–128.
16. Solid pseudopapillary tumor as a possible cause of acute pancreatitis. / J.Sakagami,K. Kataoka, Y.Sogame [et al.]// *J. Pancreas (online).* — 2004. — Vol. 5.P. 348–352.
17. Solid-pseudopapillary tumor of the pancreas (Frantz tumor) in children: report of four cases and review of the literature /W. Rebhandl, F.X.Felberbauer, S. Puig[et al.]// *J. Surg. Oncol.* — 2001. — Vol. 76. — P. 289–296.
18. Therapeutic strategy of papillary cystic and solid neoplasm: a rare non-endocrine tumor of the pancreas in children /A.Raffel, K.Cupisti, M. Krausch[et al.] // *Surg.Oncol.* — 2004. — Vol.13. — P. 1–16.

Gruber-Frantz tumor

A. P. Koshel^{1,2}, S. S. Klokov^{1,2}, K. M. Popov¹, S. V. Vtorushin^{2,3}, M. V. Zav'yalova^{2,3}, I. V. Stepanov^{2,3}, T. V. Dibina¹, Y. B. Mironova^{1,4}, Y. S. Drozdov³, V. A. Avkhimenko⁵

¹Medical center n. a. G. K. Zherlov, Seversk, Russian Federation

²Siberian State Medical University, Tomsk, Russian Federation

³Tomsk Research Institute of Oncology, Tomsk, Russian Federation

⁴Tomsk Regional Oncological Clinic, Tomsk, Russian Federation

⁵Siberian Federal Research & Clinical Centre of the Federal Medical & Biological Agency, Seversk, Russian Federation

Key words: pancreas, pancreatic tumor, Frantz tumor, immunohistochemistry, treatment

The result of treatment of a young female patient with solid pseudopapillary tumor of the pancreas is reported. This tumor is extremely rare and is revealed, as a rule, accidentally during periodic screening or when the tumor achieves the large size. The presence of a cyst on the pancreas should be considered, in particular, from the position of possible detection of a solid pseudopapillary tumor. The disease prognosis is favorable, recurrence is rare.

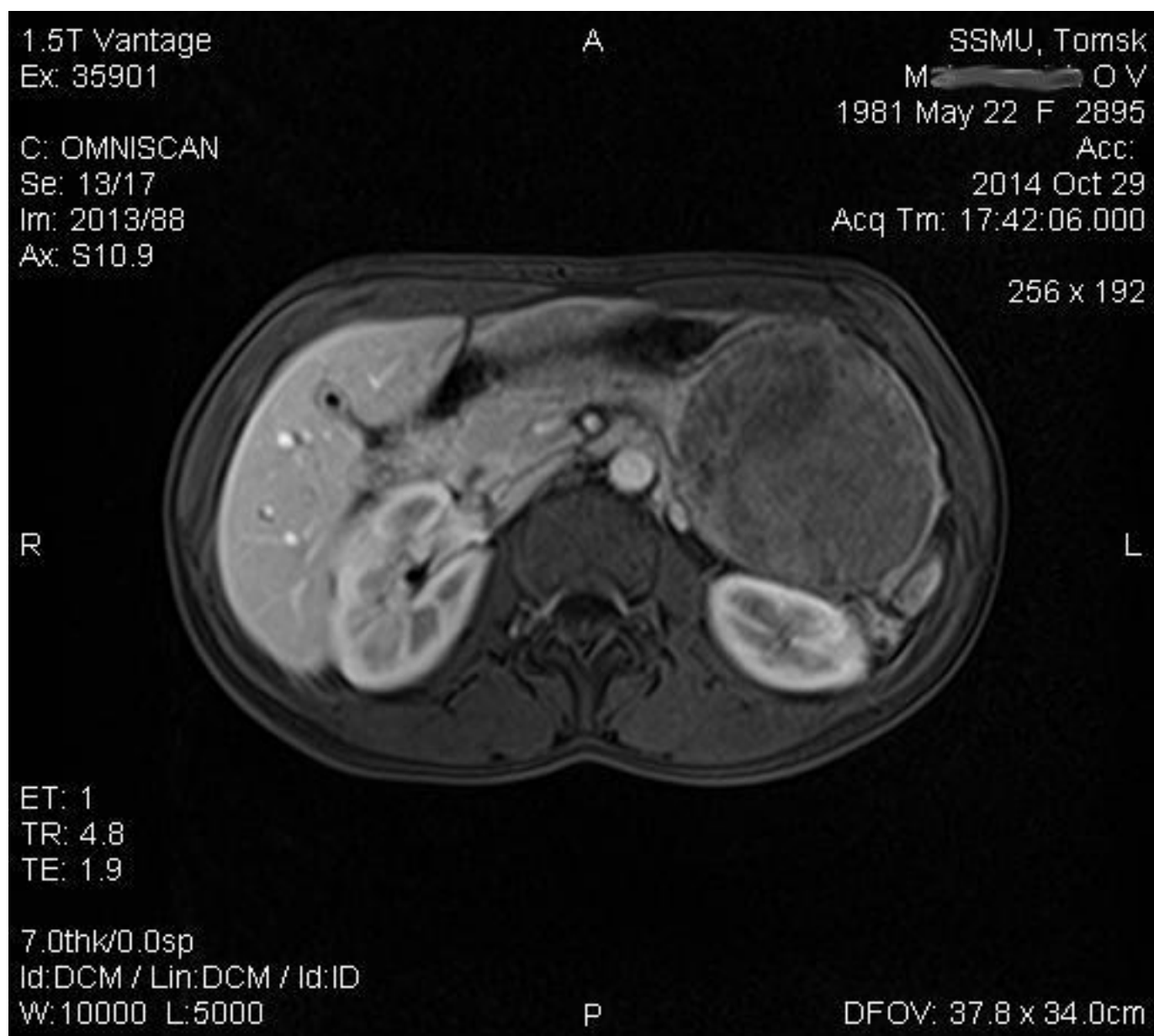
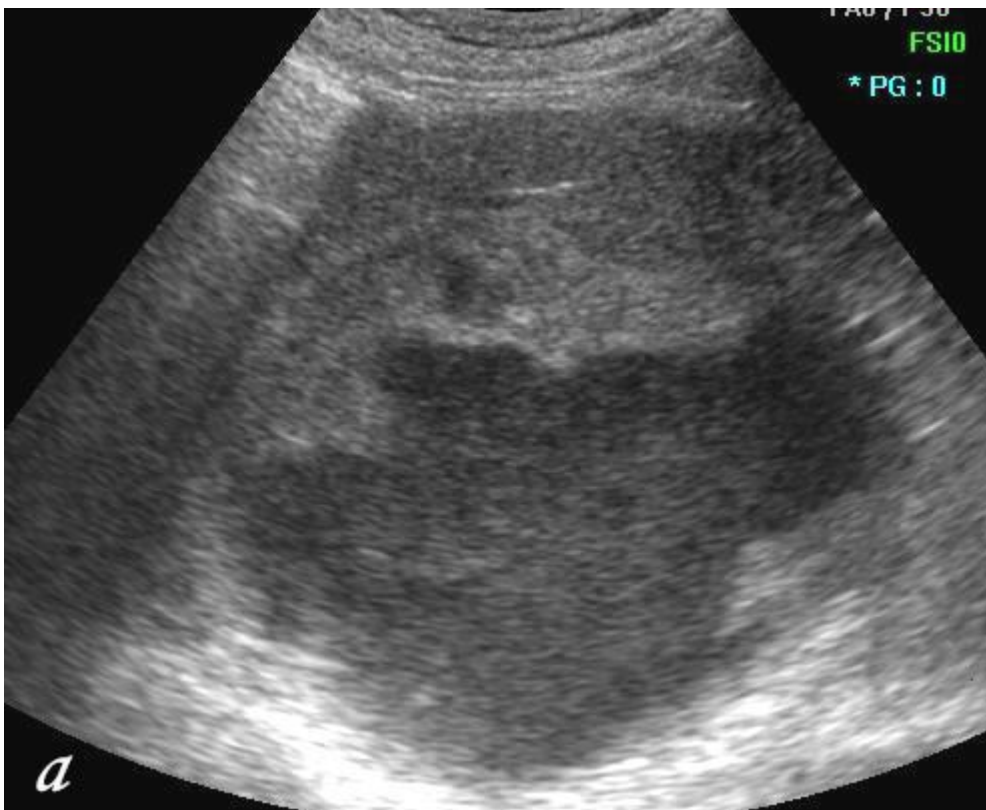


Fig. 1. MRI: a cyst in the projection of the tail of the pancreas (described in the text).

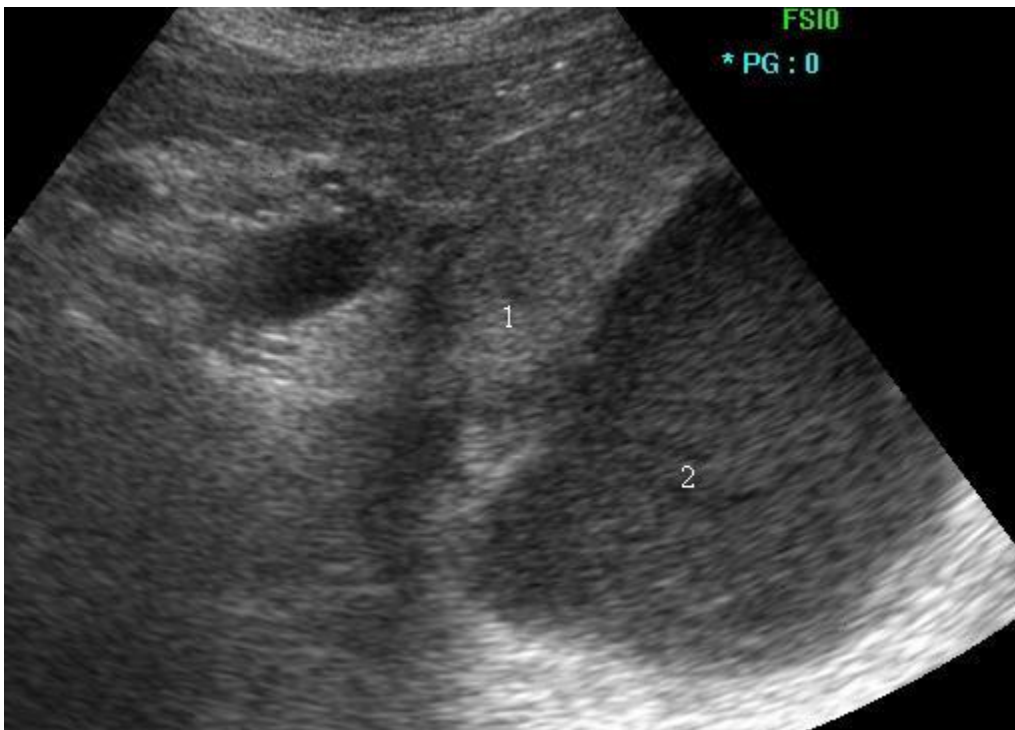

Fig. 2. Transabdominal ultrasound, 2D mode — cystic formation in the projection of the tail of the pancreas: 1 — pancreas; 2 — cystic formation with heterogeneous content.



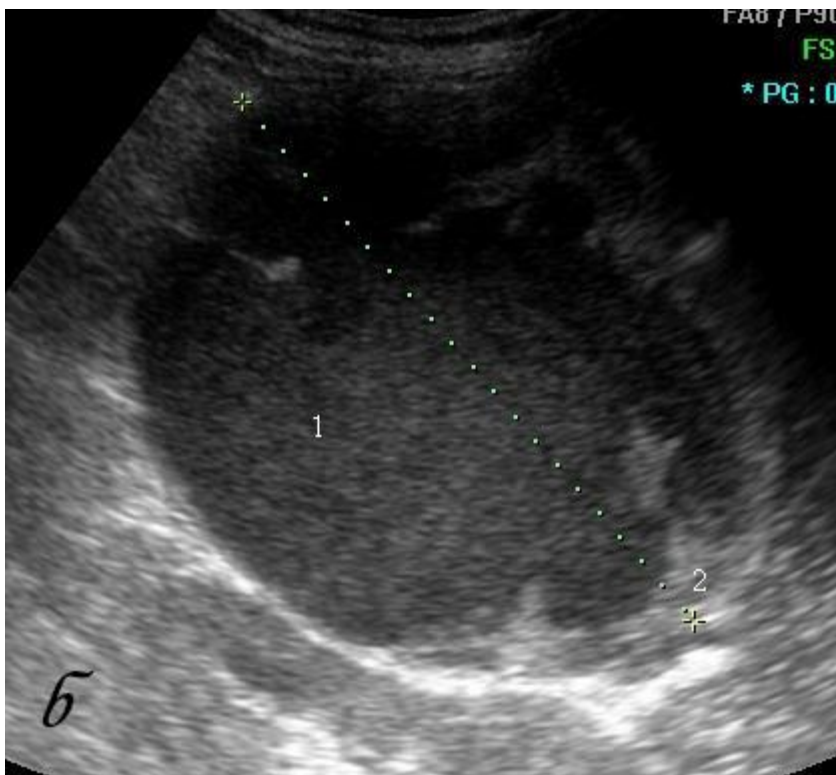
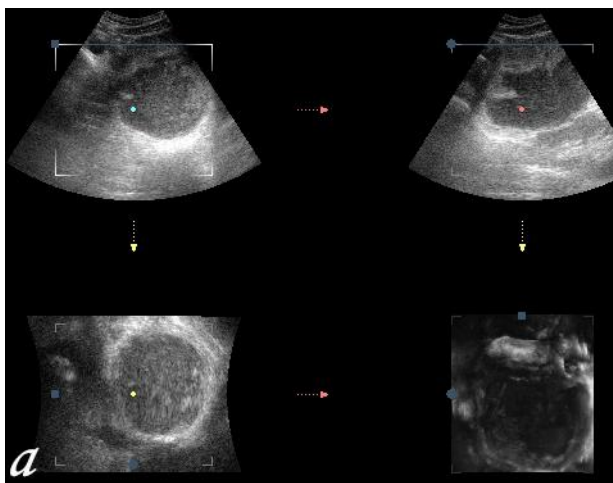


Fig. 3. Transabdominal ultrasound, 2D mode — a) irregularly thickened wall of cystic formation by overlapping with hyperechoic heterogeneous structure; b) 1 — cyst cavity; 2 — the wall of the cyst.



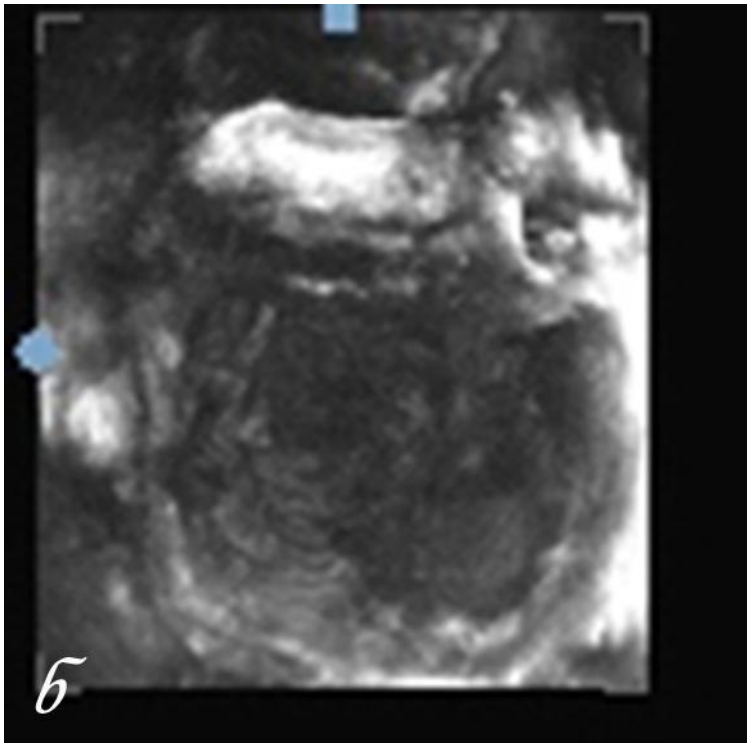


Fig. 4. Transabdominal ultrasound, 3D mode — a) three mutually perpendicular planes form a three-dimensional array; b) a three-dimensional reconstruction — cystic formation with a thick, lumpy inner loop.

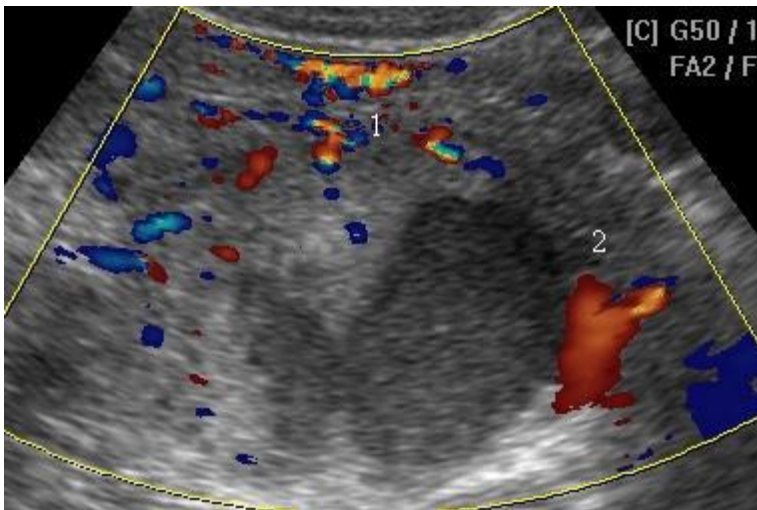


Fig. 5. Transabdominal ultrasound mode DRC: 1 — vessels of the tail of the pancreas pushed anterior cystic formation; 2 — "vascular pedicle" of formation.

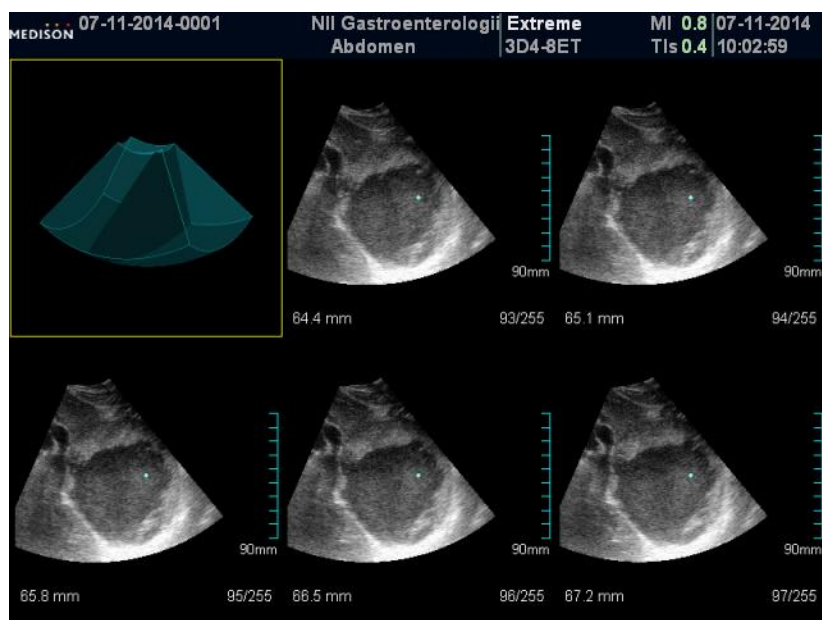


Fig. 6. Transabdominal ultrasound, 3D mode, the function multislice step cut of 0.7 mm — bond formation with pancreatic parenchyma.

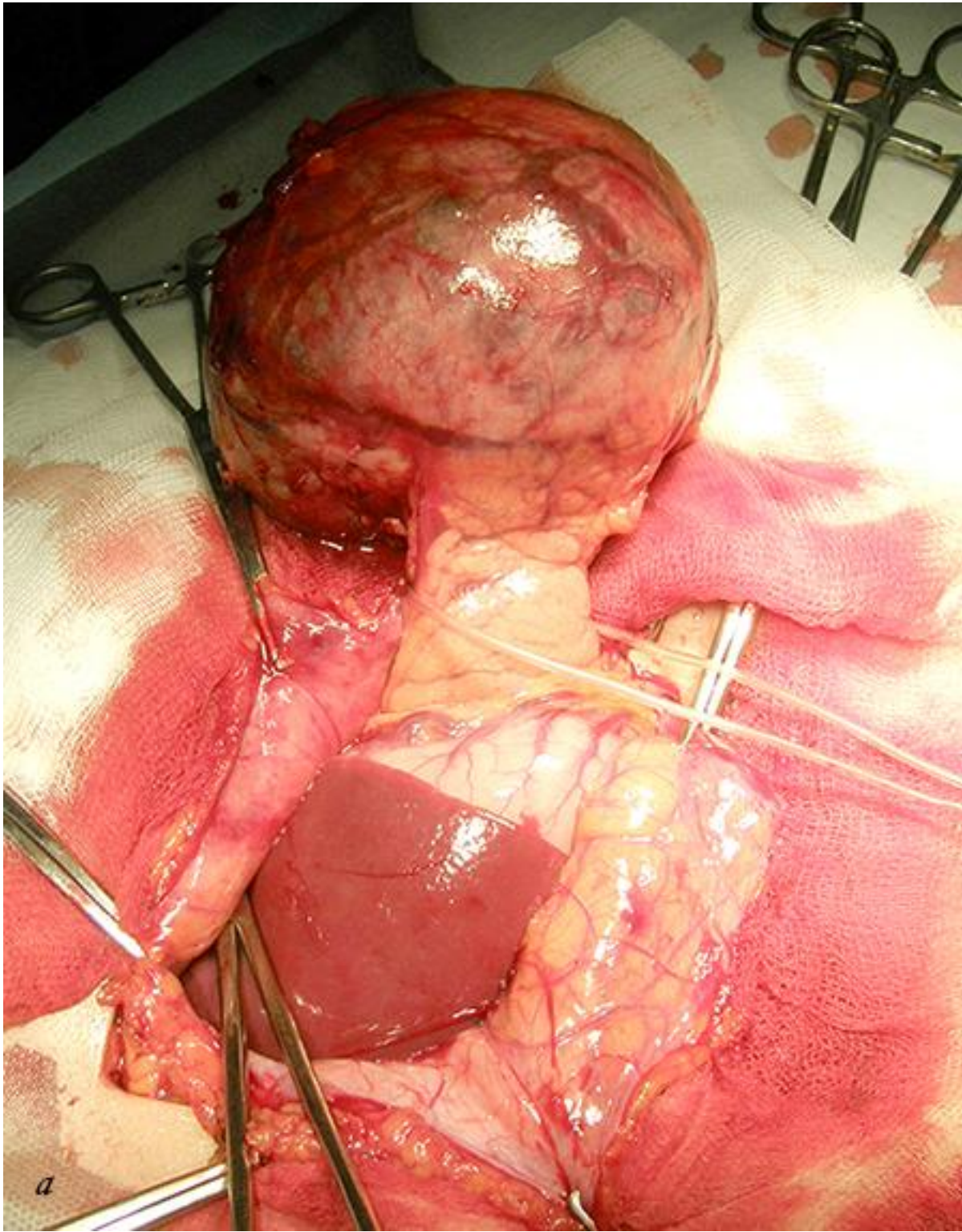

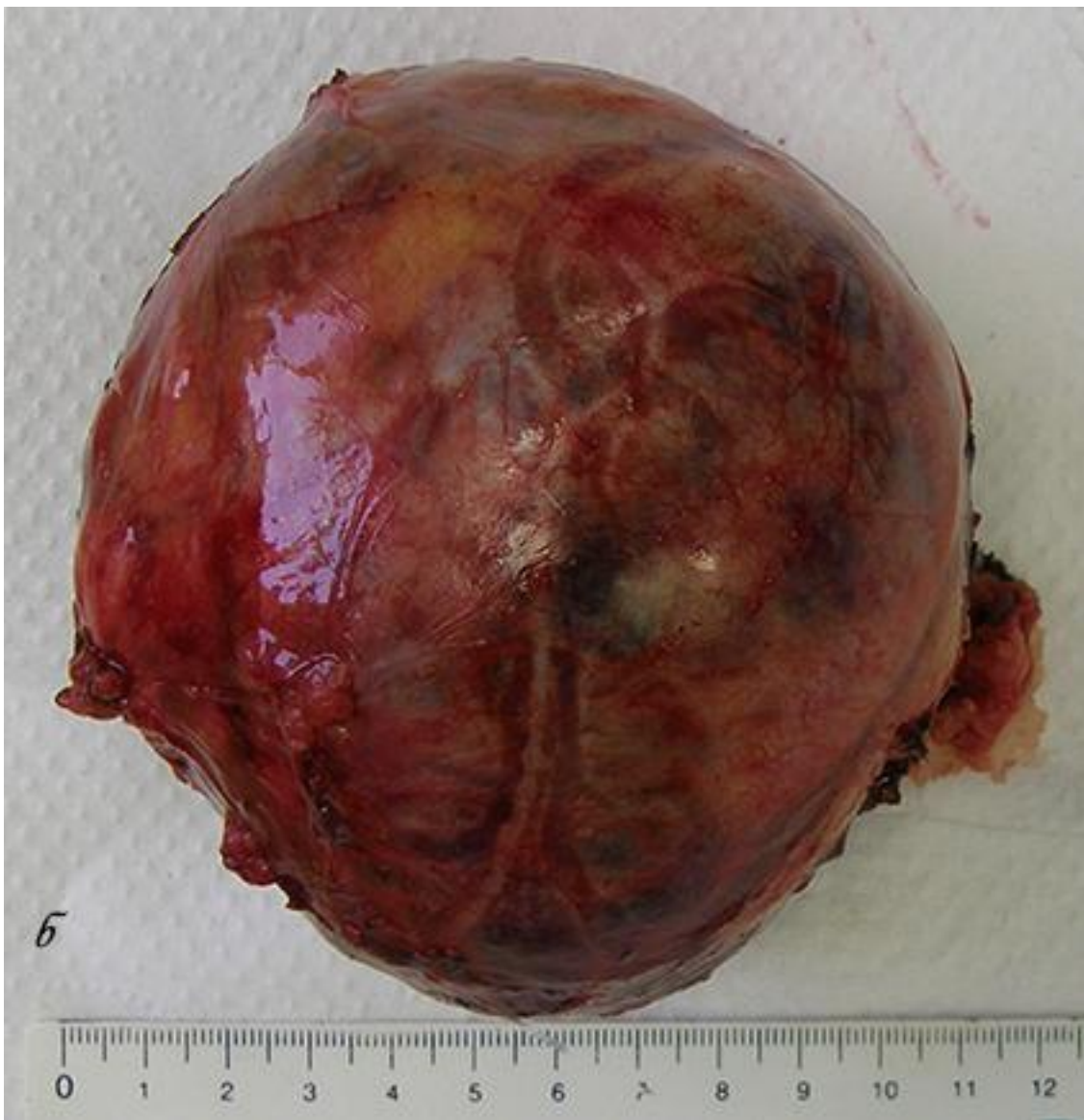


Fig. 7. a) cyst derived wound in the anterior abdominal wall; b) removal of the cyst (described in the text).

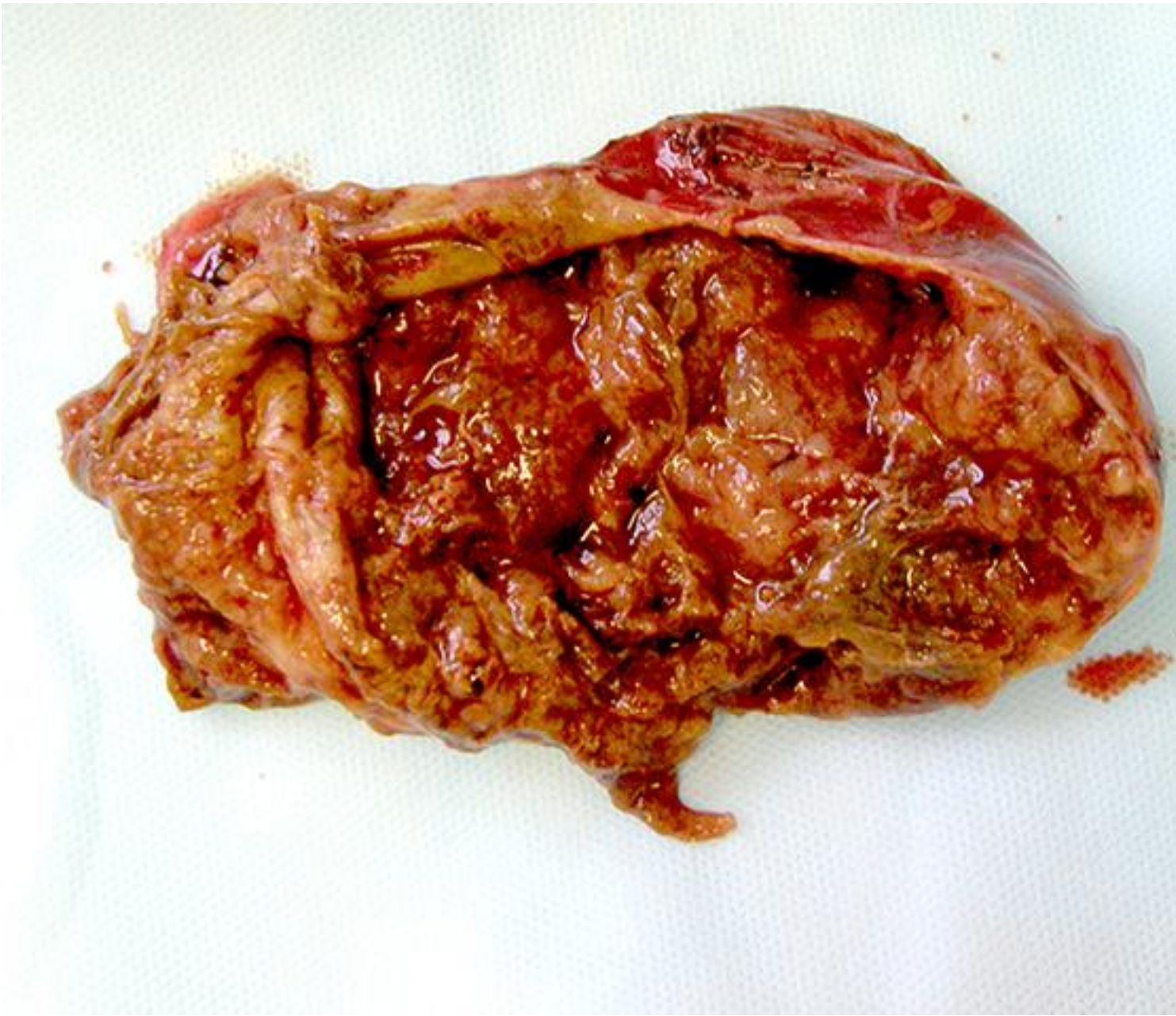
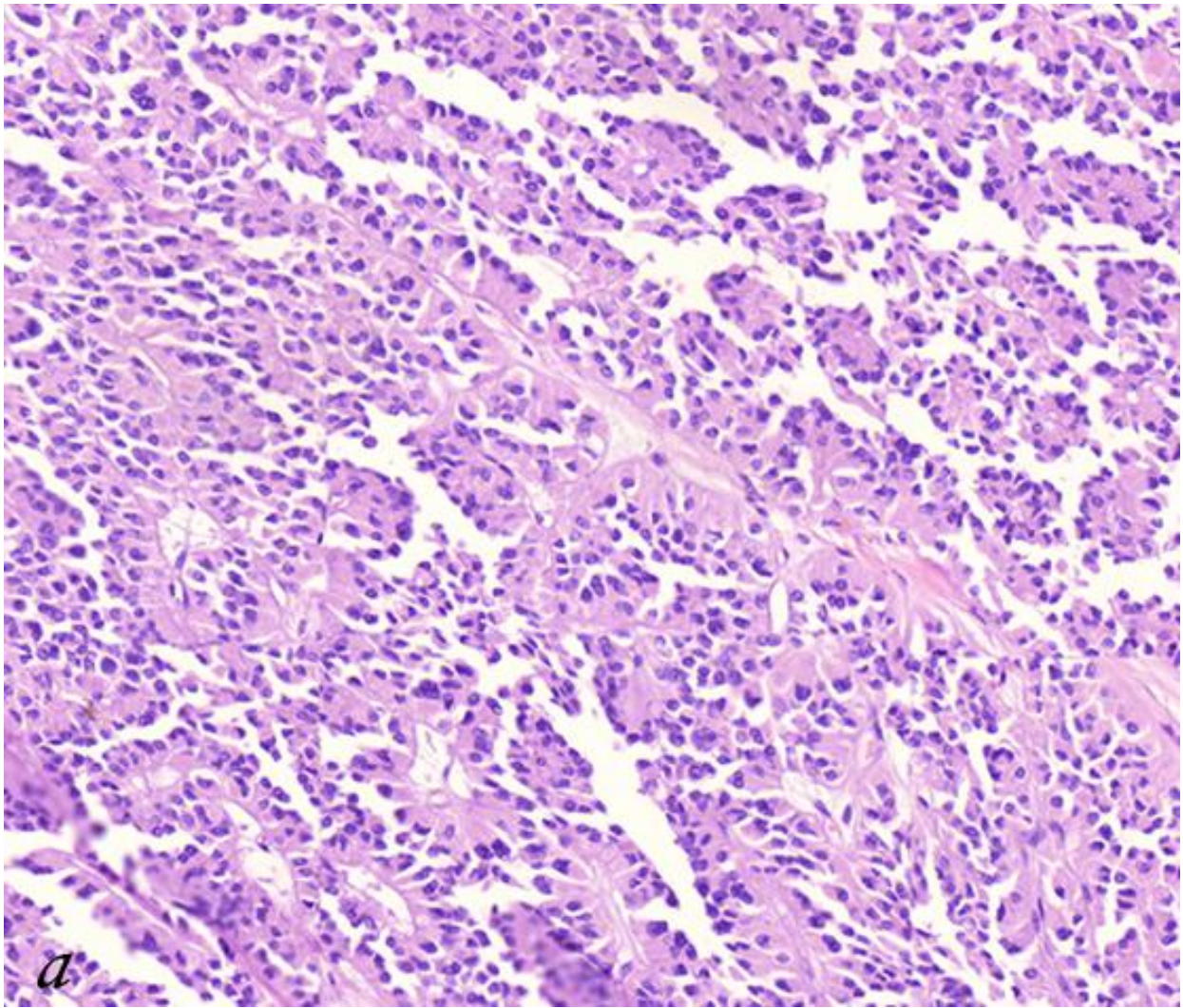


Fig. 8. Macropreparations. New formation of solid-cystic structure on the section (described in the text).



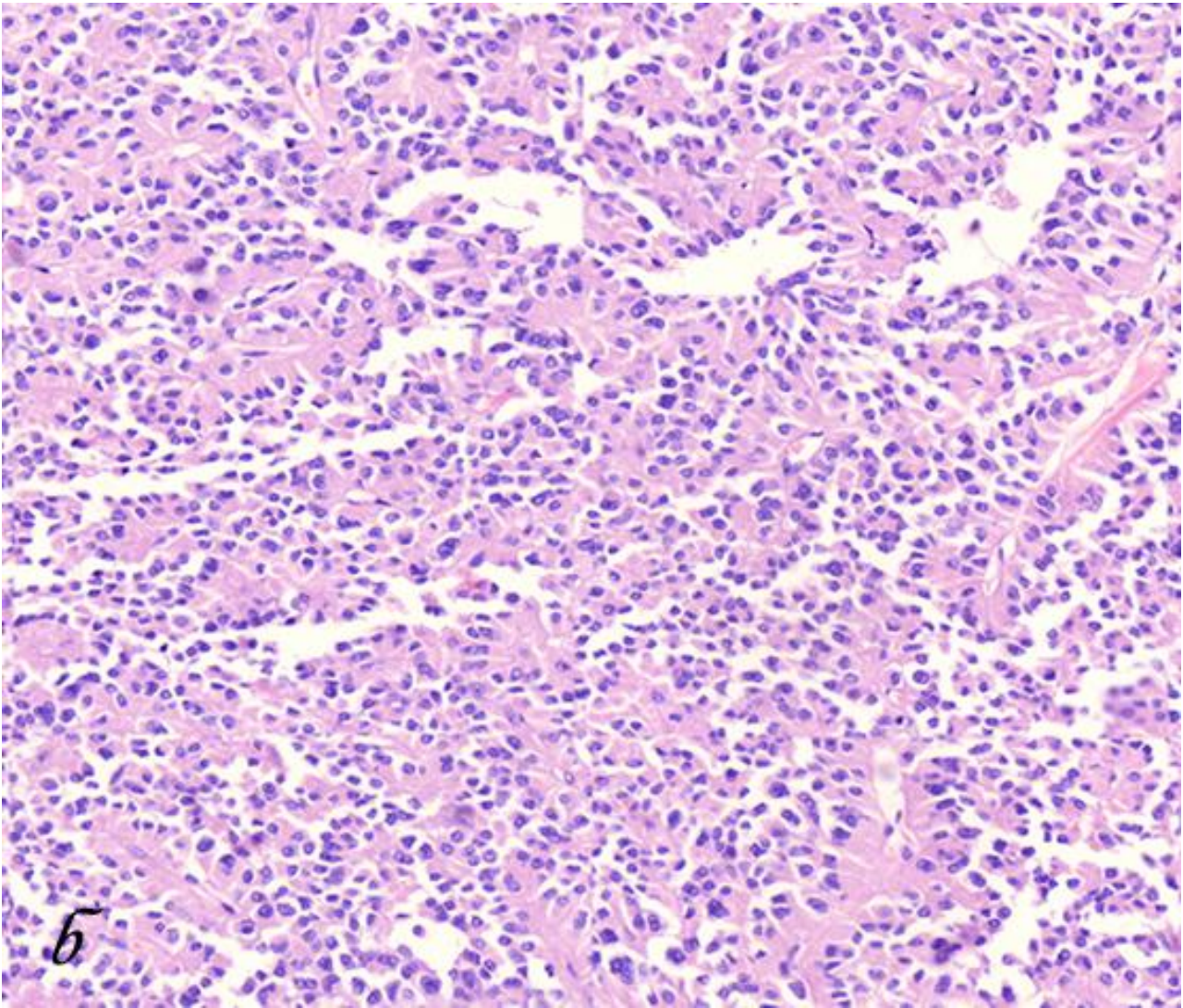
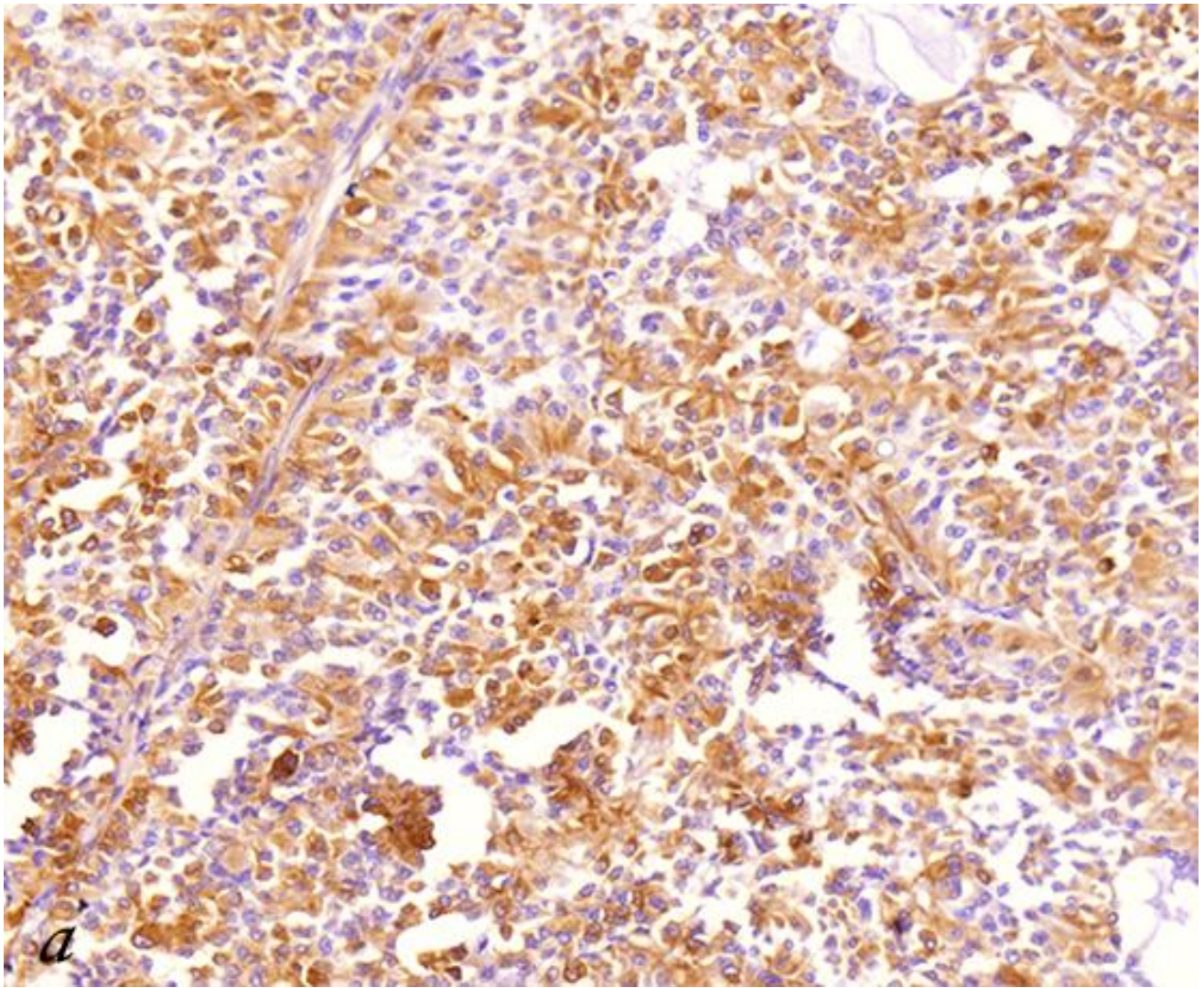
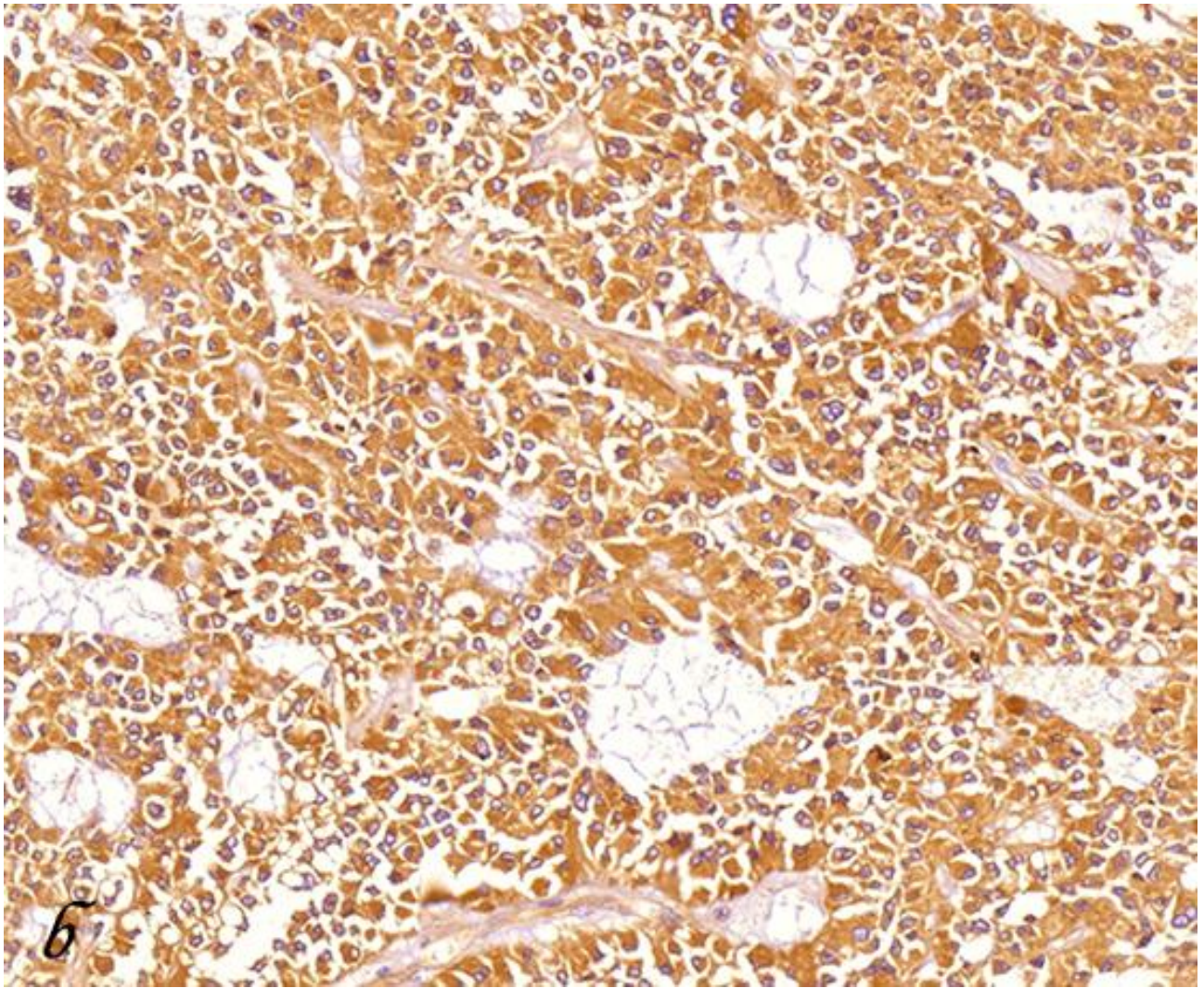
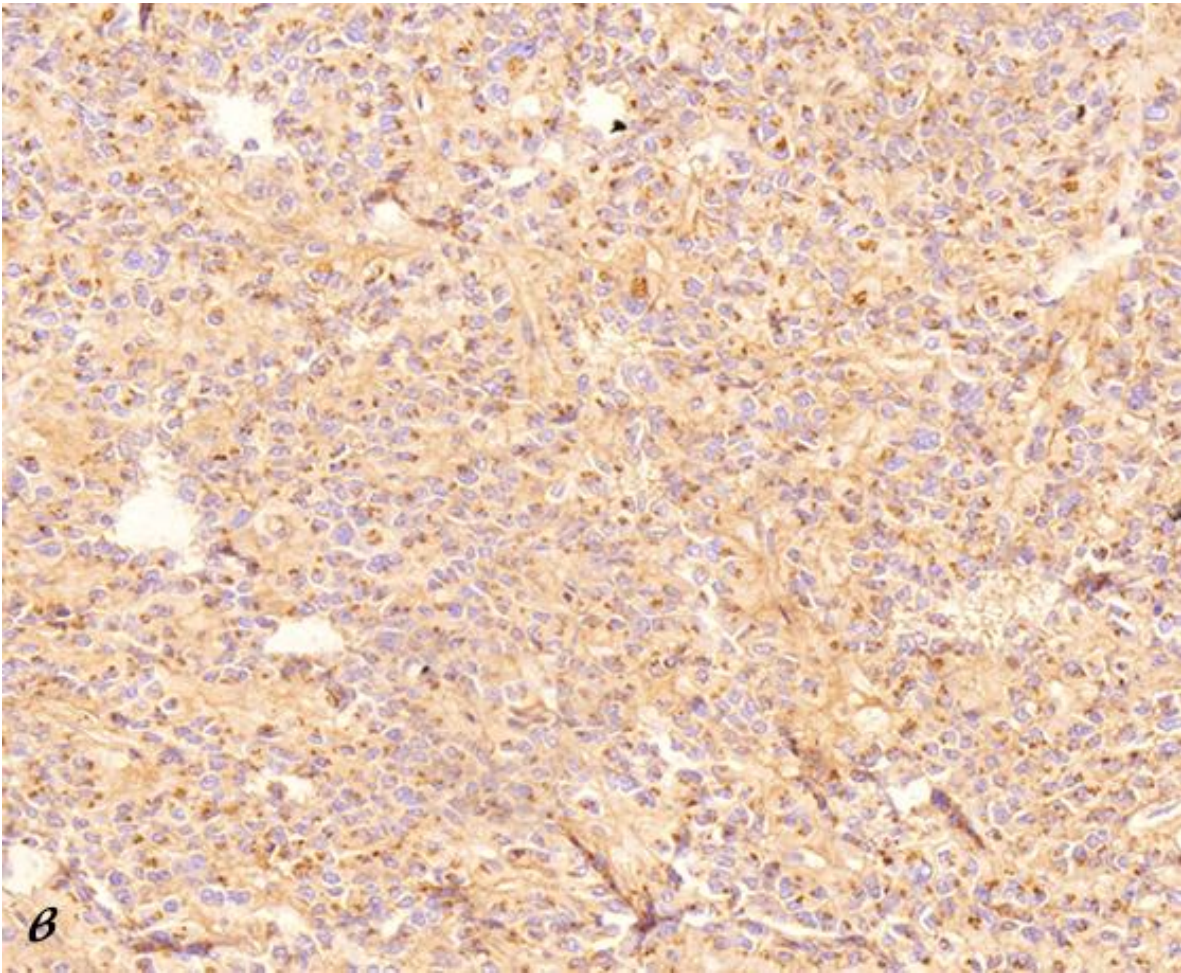
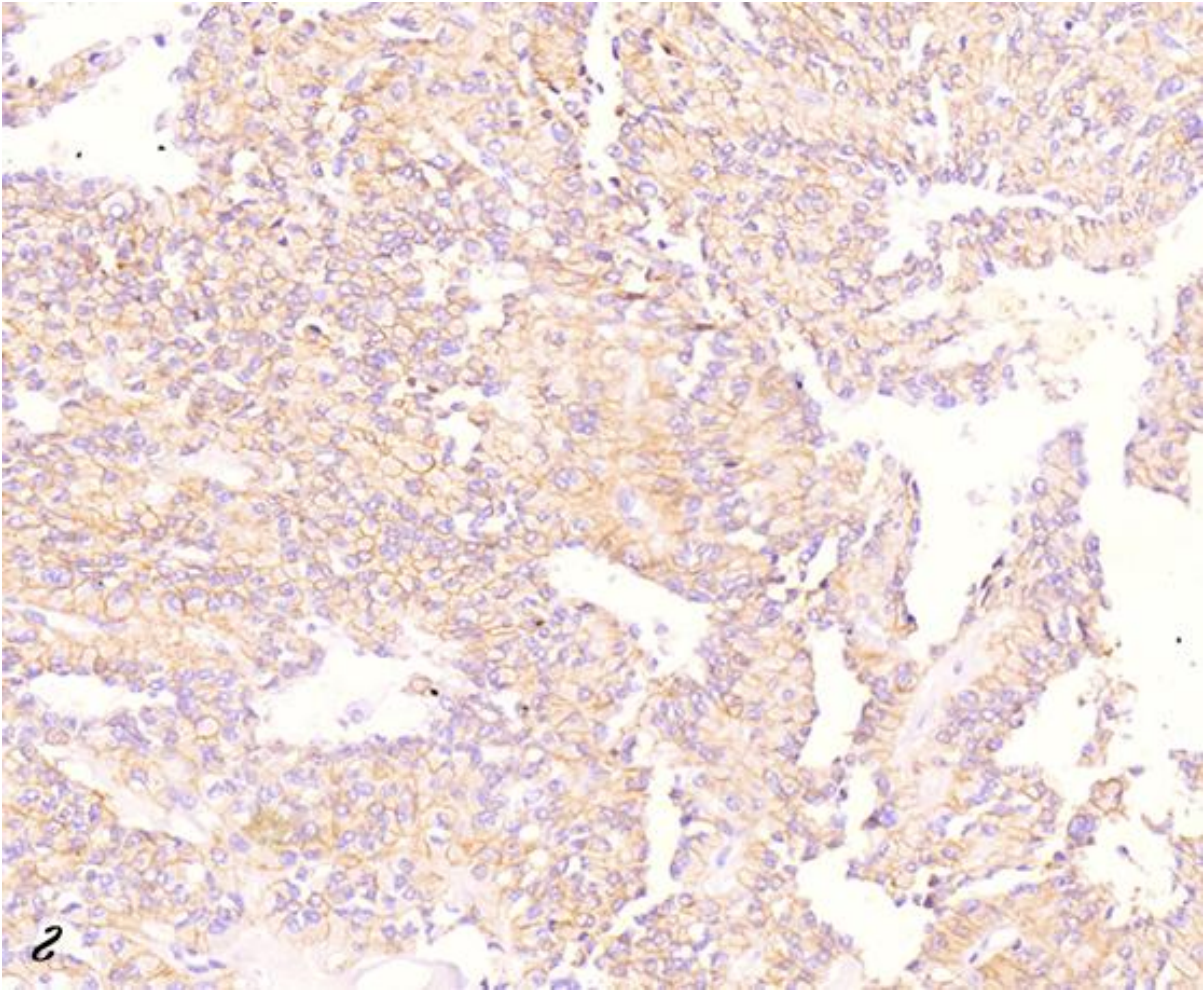


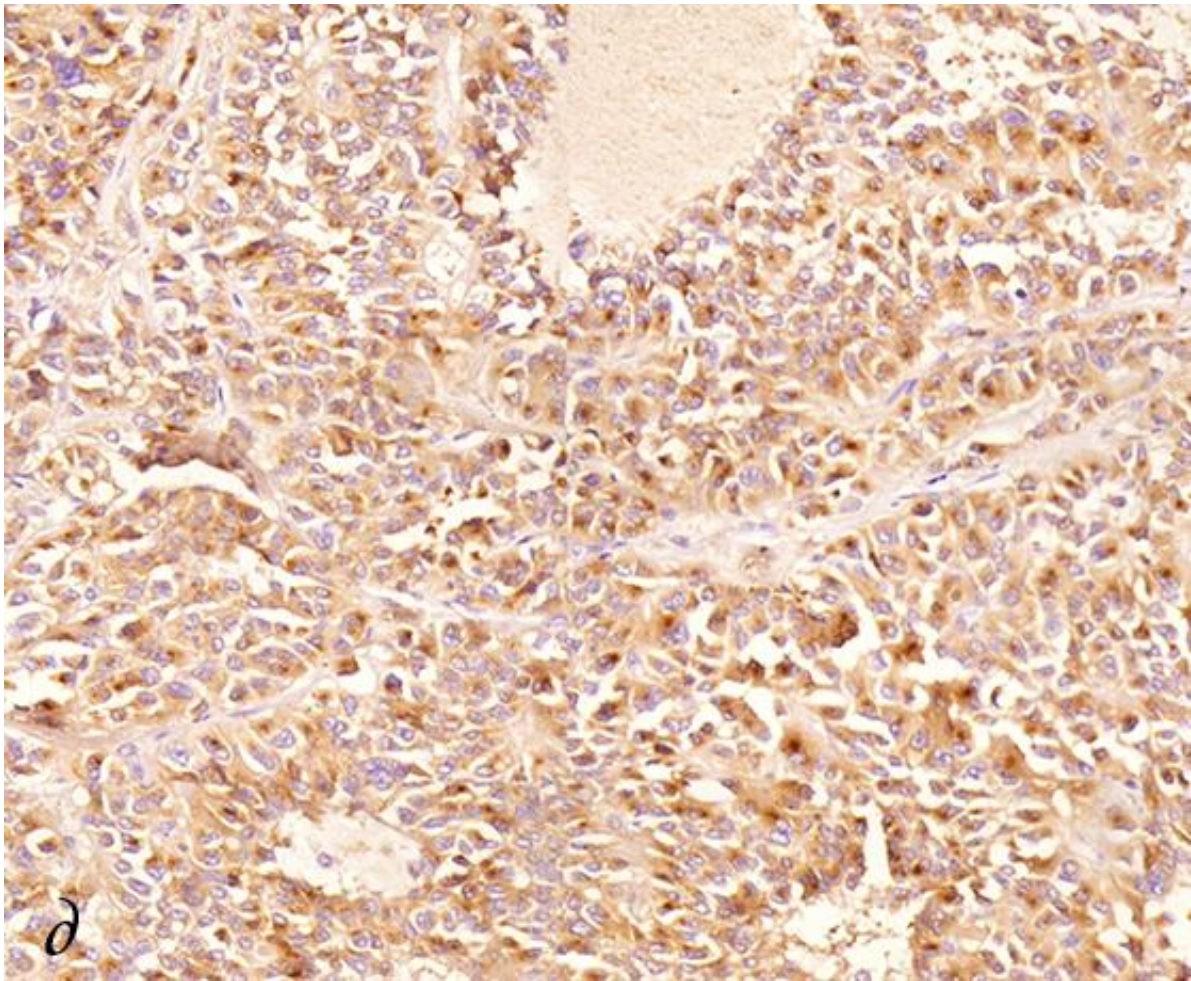
Fig. 9. Solid pseudopapillary pancreatic tumor (H & E stain, ×400): a) papillary structures in the tumor; b) structure of the solid portions of the tumor.











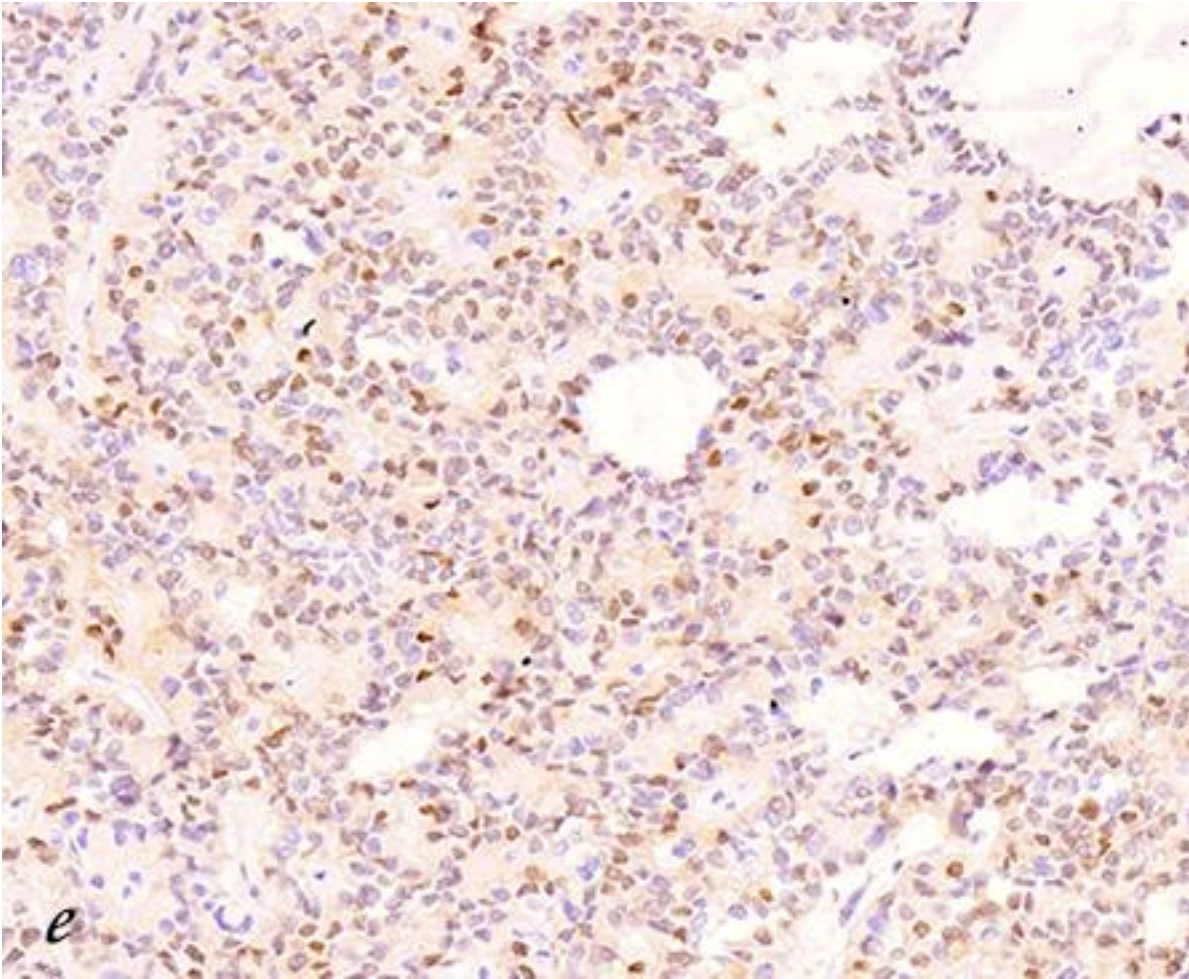


Fig. 10. Solid pseudopapillary tumor of the pancreas (immunohistochemistry, $\times 400$): a) a positive cytoplasmic staining of tumor cells to vimentin; b) expressed a positive cytoplasmic staining of tumor cells to α -1 antitrypsin; c) dot-like positive staining of cancer cells to CD99; d) a positive membrane staining of tumor cells to CD56; e) cytoplasmic and perinuclear dot-like staining of tumor cells to CD10; f) a positive nuclear expression of cyclin D1 in tumor cells.